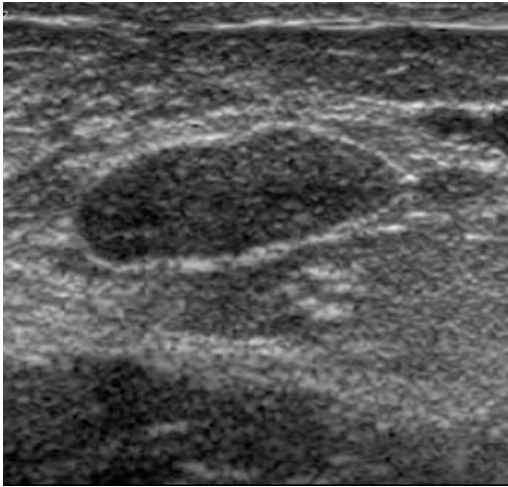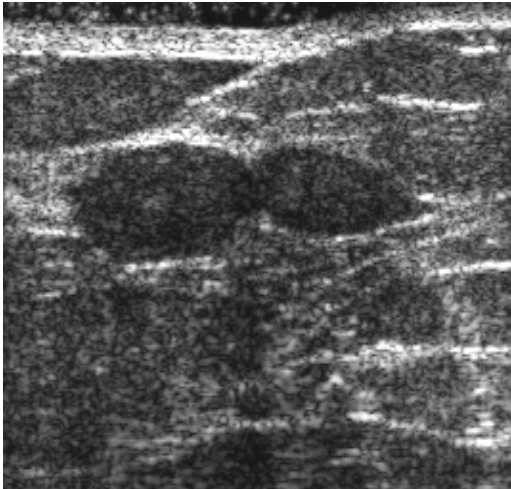

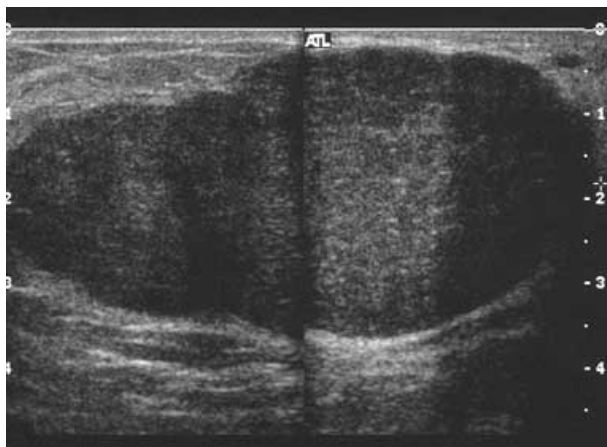
Classic Fibroadenoma



Multiple Fibroadenoma



Giant Fibroadenoma of 14 yof

On Sonography, a fibroadenoma appears:

- ⌘ Round, oval or lobulated
- Well-defined borders
- Mildly hypoechoic or isoechoic
- Homogeneous
- ⌘ Thin, echogenic pseudocapsule
- ⌘ Wider than Tall
- May compress (due to soft nature)
- Edge shadowing
- No significant enhancement or shadowing
- Peripheral and internal flow may be detected by Doppler

### **Juvenile (Giant) Fibroadenoma**

⌘ Juvenile fibroadenoma seen in adolescent girls, is a highly cellular type of benign fibroadenoma. These tumors grow rapidly and may measure up to 5cm. Doppler signal could be increased due to vascularity required to accommodate growth. They can get large enough to impinge on breast development, so they are usually surgically removed.