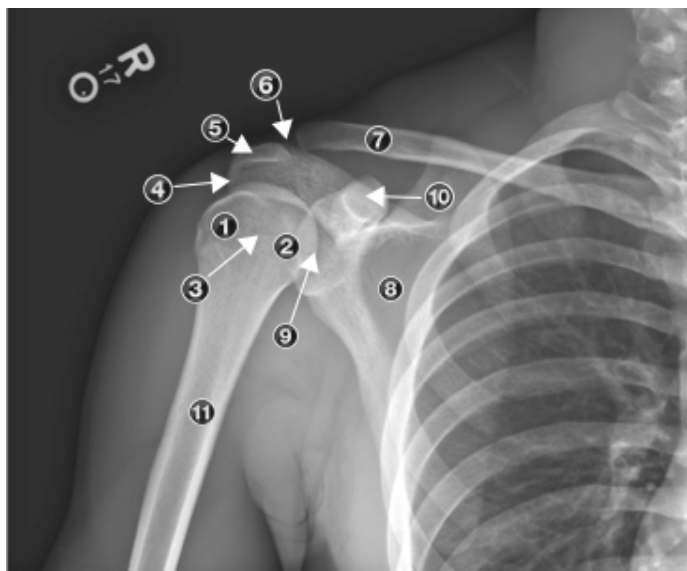


Musculoskeletal Ultrasound Review

- Acromioclavicular joint
 - True synovial joint that contains articular cartilage and a cartilaginous disc.
- Sternoclavicular joint
 - Connects the shoulder girdle to the axial skeleton.
- Scapulothoracic joint
 - Not a true synovial joint.



□ Xray anatomy of shoulder:

1. Greater tuberosity
2. Lesser tuberosity
3. Bicipital groove
4. Subacromial space
5. Acromion
6. Acromioclavicular joint
7. Clavicle
8. Body of scapula
9. Glenohumeral joint
10. Coracoid process of scapula
11. Humeral shaft

